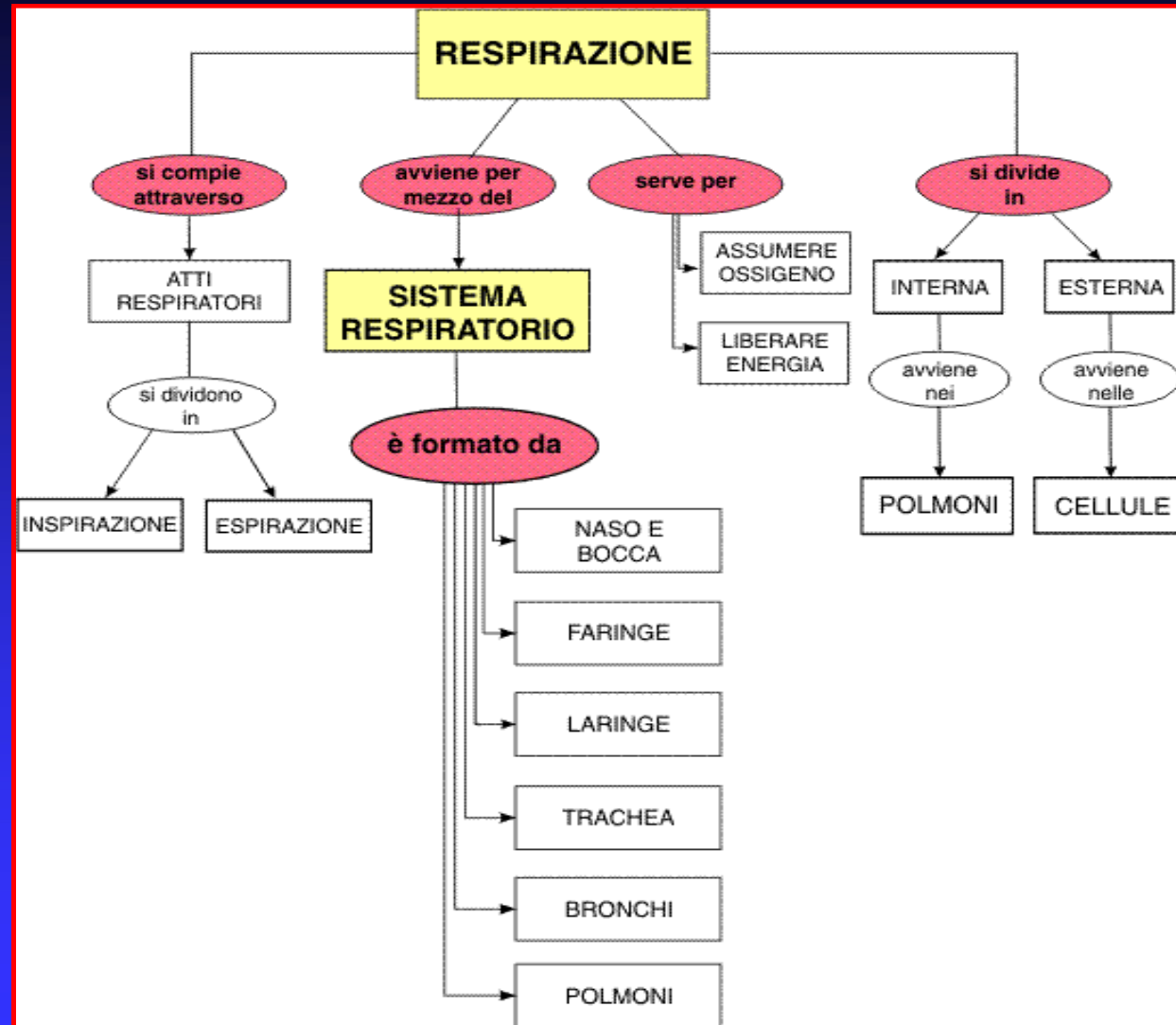


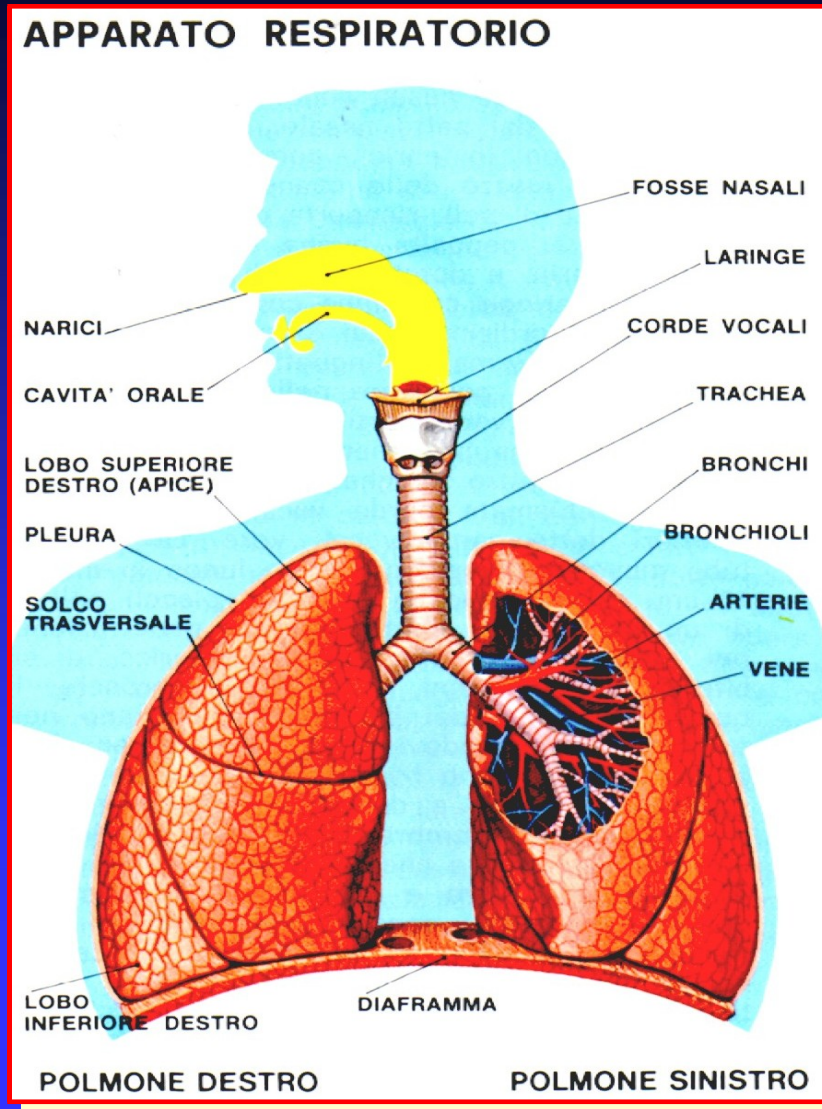
# APPARATO RESPIRATORIO



# APPARATO RESPIRATORIO

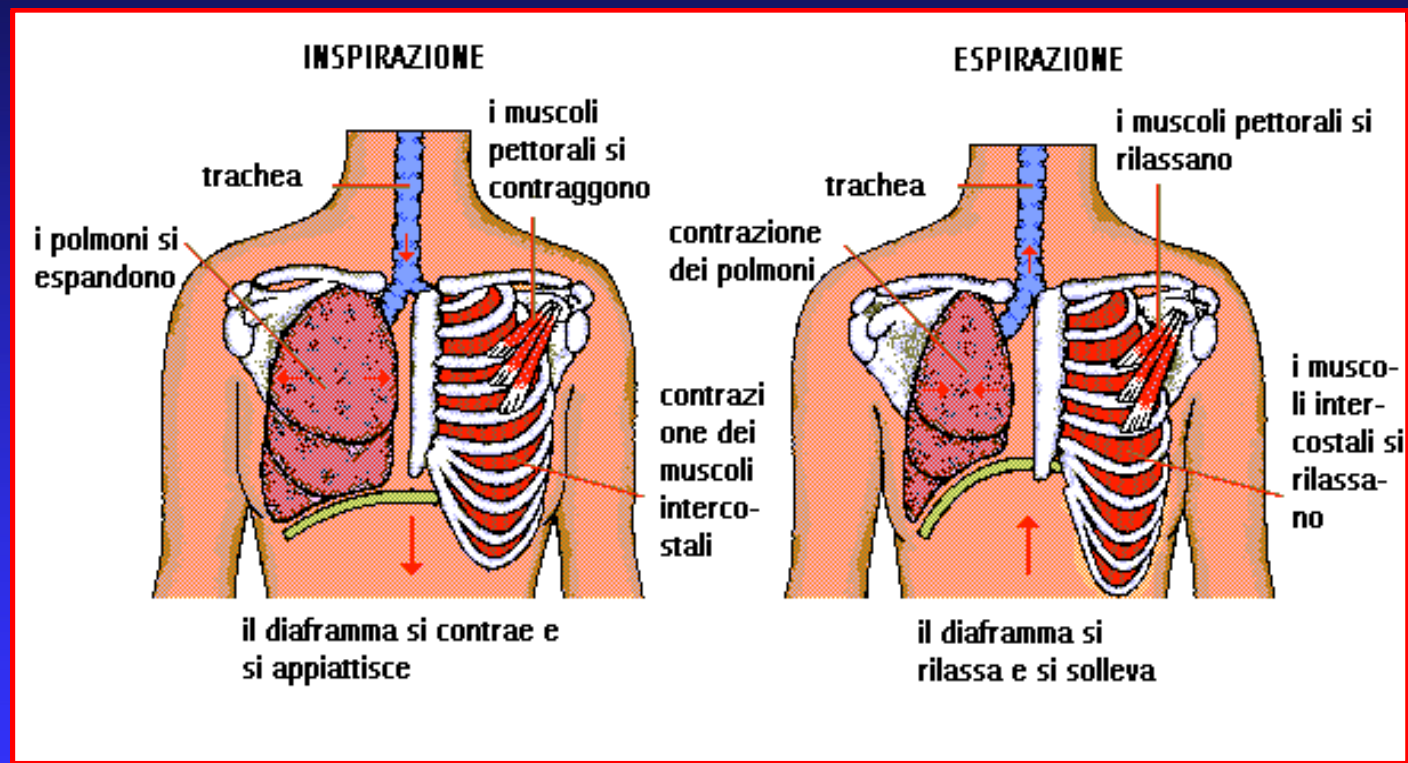


UNITA' ANATOMICHE  
MACROSCOPICHE DEL  
SISTEMA RESPIRATORIO



# APPARATO RESPIRATORIO

## MECCANICA DELLA RESPIRAZIONE

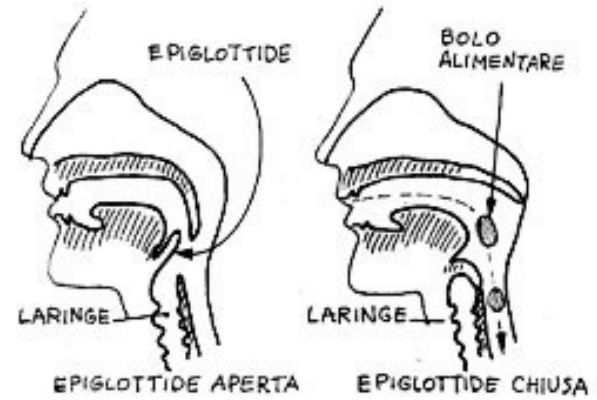
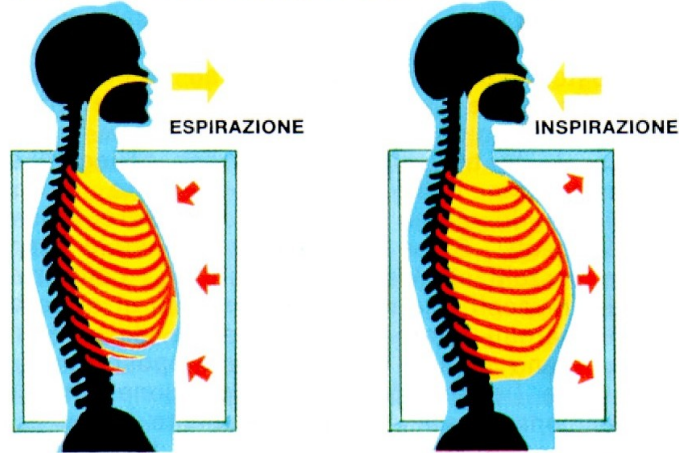


# APPARATO RESPIRATORIO

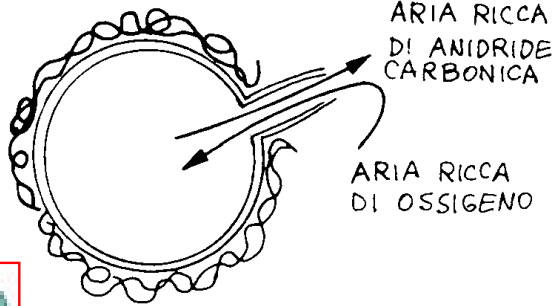
	ISPIRAZIONE	ESPIRAZIONE
	<p>Contrazione di:</p> <ul style="list-style-type: none"> <li>- Intercostali esterni</li> <li>- Diaframma</li> </ul>	<p>Rilassamento di:</p> <ul style="list-style-type: none"> <li>- Intercostali esterni</li> <li>- Diaframma</li> </ul>
RESPIRAZIONE NORMALE	<ul style="list-style-type: none"> <li>- Sopra e Sottoioideo</li> <li>- Scaleno anteriore, medio e superiore</li> <li>- Sternocleidomastoideo</li> <li>- Succlavio - Elevatori delle coste</li> <li>- Piccolo pettorale - Gran pettorale</li> <li>- Ileocostale del collo</li> <li>- Elevatore della scapola</li> <li>- Trapezio - Dentato posteriore superiore</li> <li>- Gran dentato - Gran dorsale</li> </ul>	<ul style="list-style-type: none"> <li>- Trasverso dell'addome</li> <li>- Obliquo esterno</li> <li>- Obliquo interno</li> <li>- Retto dell'addome</li> <li>- Triangolare dello sterno</li> <li>- Dentato posteriore inferiore</li> <li>- Quadrato dei lombi</li> </ul>
RESPIRAZIONE FORZATA		

# APPARATO RESPIRATORIO

## GABBIA TORACICA (ESPANSIONE)

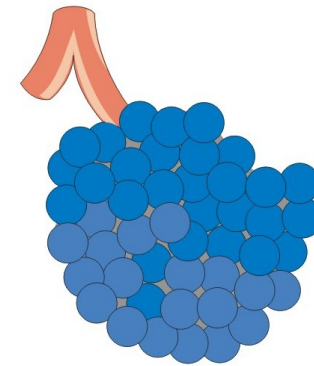


ALVEOLO  
POLMONARE

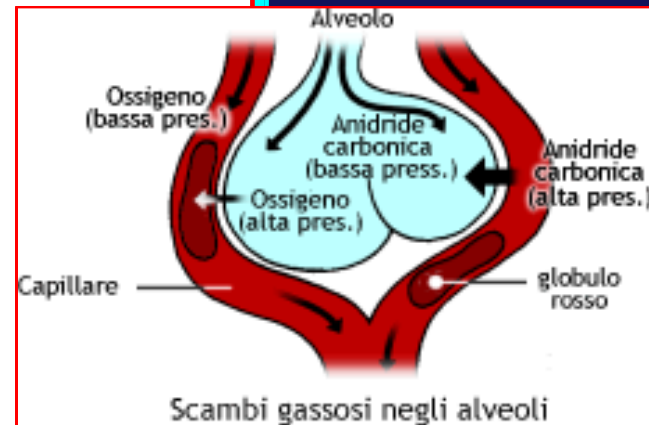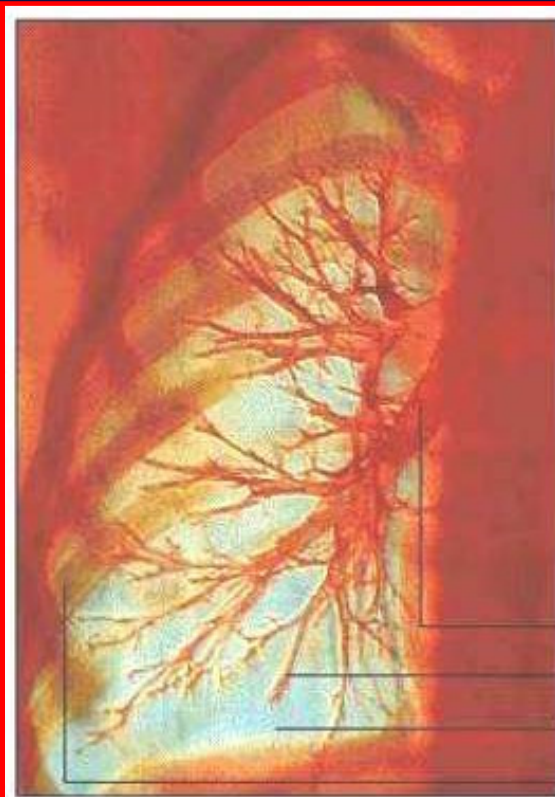


MITOCONDRIO

GRAPPOLO DI  
ALVEOLI POLMONARI



# APPARATO RESPIRATORIO



Pulmonary artery  
Artery  
Lung  
Rib cage

